

Research Article**Evaluation of antifertility potential of Ketoconazole and assessment of its reversible effect on concomitant treatment with Metformin and Hydroxytyrosol in rats****J. Anbu^{1*}, Shah Akshay Mahendra¹, Lakshmi M. Sundar², Ramya P. S. Reddy¹, Damodar Nayak¹**¹Department of Pharmacology,

Faculty of Pharmacy, M. S. Ramaiah University of Applied Sciences, Bengaluru, Karnataka-560054 India

²Department of Pharmaceutical Chemistry,

Faculty of Pharmacy, M. S. Ramaiah University of Applied Sciences, Bengaluru, Karnataka-560054 India

Received: 26 July 2018

Revised: 14 August 2018

Accepted: 2 September 2018

Abstract

Objective: In the present study, we aimed to evaluate antifertility potential of Ketoconazole and influence of Metformin in normalization of infertility with the support of strong antioxidant Hydroxytyrosol as a supplementary agent. **Materials and Methods:** To fix the combinational therapeutic dose the toxicological assessment was done and found to be non-toxic at maximum of 20mg/kg dose level. In the in vivo pharmacological studies, we tested the toxic effect of Ketoconazole alone and its normalization effect in the formulated Ketoconazole and Metformin with Hydroxytyrosol 20mg/ml suspension (KMH) at 5, 10, 20 mg/kg. p.o. on the epididymal spermatozoa. The adult male rats were exposed to KMH for 14 days. The rats (n=6) were grouped as normal control group received 2% CMC alone as vehicle. Second group of animals served as positive control treated with only Ketoconazole as male infertility agent. Third group of rats were administered with KMH for 14 days and left untreated for further period of 14 days. **Results:** Ketoconazole treatment resulted in a significant decrease in the epididymal sperm count, motility and viability and increased incidence of sperm abnormalities. However, the toxic effect of Ketoconazole was reversible in the KMH group. Thus, the present investigation suggests that the chronic treatment of ketoconazole is capable of inducing male infertility and supplementation with Metformin and Hydroxytyrosol combinational therapy significantly ($P < 0.01^{**}$) helps in regaining the mating behavior, number of spermatozoa in the Cauda epididymis, motility of spermatozoa, weights of testes, epididymides, vas deferens and prostate were normalized. The micro anatomical architecture of male reproductive organs, mating behavior and F1 litter size and other biochemical parameters in this group confirms the reversal effect of fertility with normal reproductive character in the male rats. **Conclusion:** Based on the results obtained in this study, it is concluded that the combination of Ketoconazole, Metformin and Hydroxytyrosol at the dose level used can be used to induct safe and reversible male infertility.

Keywords: Antifertility, Ketoconazole, Metformin, hydroxytyrosol, microanatomical, Cauda epididymis

Introduction

Male contraceptive measures have been popularly confined to condoms and vasectomy. The advantage of protection against the spread of venereal diseases has made condoms as preferred temporary contraceptive of choice in men. In contrast, advances in male-directed methods have been confined to refinements in

the type of condom and technique of vasectomy. Yet despite their limitations, up to 30% of couples worldwide use a male method of contraception (Gray et al., 2006). According to WHO report 67 percent of all women currently use non-permanent birth control methods, primarily hormonal methods. About 25 percent of these women rely on taking daily birth control pills, even though most are aware “the pill” affects their entire body. (Samba Reddy, 2008) Synthetic hormonal oral contraceptives are therefore the most prevailing and most commonly used concept (Welling, 2016; Carlsen and Vanky, 2010).

A milestone in the development of spermicides was the discovery in the early 1950s of the efficacy of the detergents

***Address for Corresponding Author:**

Dr. J. Anbu, Professor

Department of Pharmacology, Faculty of Pharmacy

M.S. Ramaiah University of Applied Sciences, MSR Nagar, Bangalore, Karnataka, India- 560054

E-mail: anbucologist@gmail.com

DOI: <https://doi.org/10.31024/ajpp.2019.5.1.1>2455-2674/Copyright © 2019, N.S. Memorial Scientific Research and Education Society. This is an open access article under the CC BY-NC-ND license (<http://creativecommons.org/licenses/by-nc-nd/4.0/>).

typified by nonoxynol-9. Boys have been shown to have elevated levels of both oestrogens and androgens when compared with girls (Carlsen and Vanky, 2010). Desmographic reports of Ketoconazole have shown remarkable efficacy for fungal infections, it is known to affect the testis and continual use could impair fertility. This study was therefore undertaken to determine whether this was the case, and if so to what extent testicular function was impaired.

Despite the remarkable efficacy of ketoconazole as an anti-fungal agent, its known effects on the testis and problems of infertility on continual use have provided impetus for performing this study. Long term administration of Ketoconazole at the dose level of 80 mg/kg/day in male rats causes oligospermia and 40 mg/kg/day in female rats did not appear to have any adverse effects, but higher doses in female rats lowered the pregnancy rate and increased still birth and pup mortality.

The common denominator between Type 2 diabetes, Metformin and infertility can be described as Insulin carries blood sugar to the body cells to create energy. Similarly, research reports indicate that Metformin has a secondary role as a fertility enhancer apart from its widely popular use as an anti-diabetic agent. Hence, the combination of Ketoconazole and Metformin was selected and an attempt has been made to evaluate for their reversible male antifertility response. In addition, in order to heighten the influence of Metformin in normalization of infertility a strong antioxidant Hydroxytyrosol as a supplementary agent was included in the treatment.

Materials and methods

Preparation of Suspension and its characterization

Accurately weighed 0.5mg of Ketoconazole, Metformin and 0.5ml of Hydroxytyrosol was suspended in 2 ml of 2% Carboxy Methyl Cellulose (CMC) solution and administered orally using oral gavage after diluting with saline solution as per the requirement. Further to characterize the formulation, particle size using Biovis Particle size Analyzer software Version 4.59, sedimentation time, sedimentation rate and intermolecular interactions by FTIR Spectroscopic analysis to determine degree of branching, regularity of the macromolecule arrangements and degree of orientation (Cheng et al., 2012). The FTIR spectra was recorded at the scanning range of 400-4000 cm^{-1} (FTIR-8400S, Spectrophotometer, Shimadzu, Japan) (Zhang et al., 2013).

Pharmacological studies

Animals

This study was approved by the Institutional Animal Ethics Committee (IAEC) of Department of Pharmacology, Faculty of Pharmacy, M. S. Ramaiah University of Applied Sciences

(Reference no: XIX/MSRFPH/M-03/07.11.2017), Bangalore, Karnataka. Sexually mature Wistar rats weighing between 170-220g of either sex were procured from the animal house of the department and maintained on a 12-hour light and 12-hour dark cycle, and provided with food (Sai durga Foods, Bangalore) and water *ad libitum*. For animal treatments, Animals were kept for fasting before giving dose and then the weight of the animals were taken. The formulation was given orally to the rats as single dose. The control group was treated with vehicle saline or 2% CMC only. At the end of the experimental procedure, interpretations were made and documented as per the guideline.

Acute toxicity study

Acute toxicity was performed for KMH formulation as per OECD 423 method on female rats and considerable toxic symptoms was observed in animals at 100mg/kg p.o., but no mortality. Hence for further pharmacological testing 1/5, 1/10 and 1/20th doses were considered for therapy. After the drug administration, animals were individually observed once in first 30 minutes and in between in the next 24 hours with special care given in the first 4 hours and then daily for 14 days. All observations were made systematically. Weight of individual animals was recorded before and after the KMH dosing at weekly intervals. Weight changes were observed and tabulated. The animals survived till the end of study period were humanly sacrificed and subjected for gross necropsy and pathological study.

Sub-acute oral toxicity study

The acute toxicity study results indicated that the formulation KMH is safe and non-toxic up to 100mg/kg. p.o. Therefore, the doses 5, 10 and 20 mg/kg were selected for sub-acute toxicity evaluation. Ten Wistar albino rats of either sex (200-220g) 5-male and 5-female in each group were randomly divided into four groups for dosing up to 28 days. During the treatment period the animals were observed for the general behavioral pattern, body Weight, food and water consumption. Similarly, the blood samples were collected from retro orbital plexus at weekly intervals and used for hematological and biochemical analysis as described in the OECD 407 guidelines. All the animals were sacrificed on day 29 and necropsied after taking the wet weights of liver, kidney, lungs, stomach, pancreas, testes and ovaries.

Histopathology

The isolated vital organs were washed with normal saline and kept in 10% formalin for 48 hours. Paraffin sections were made at 5 mm thickness using a microtome processed

in alcohol-xylene series and stained with alum hematoxylin and eosin, mounted on the glass slide and they were subjected for histopathological examination.

Antifertility Study

Male adult Wistar rats weighing between 200-220g was used for this study and all the animals were maintained in standard laboratory conditions. During the experimental period, animals had free access to food and water.

Grouping and Treatment

I	Normal control (2% CMC)
II	Standard (Ketoconazole alone)
III	Ketoconazole + Metformin (5mg/kg)
IV	Ketoconazole + Metformin (10mg/kg)
V	Ketoconazole + Metformin (20mg/kg)
VI	Ketoconazole + Metformin + Hydroxytyrosol (20mg/kg)

Estimation of sex hormones

Blood samples were collected from rats, sera was separated for the estimation of testosterone, estrogen, prolactin (PL), Follicle Stimulating Hormone (FSH) and Luteinizing Hormone (LH) (Akaydin et al., 2014).

Assessment of sperm motility and count

The right Cauda epididymis was incised and progressive sperm motility was evaluated, for sperm count, the left Cauda epididymis was incised and placed on the Neubauer counting chamber. The total numbers of sperm cells were counted and expressed as $10^6/\text{mL}$ (Agarwal et al., 2014; Bhatia et al., 2010).

Assessment of sperm viability and morphology

A viability study was done using eosin/nigrosin stain. Viable sperm remained colorless while non-viable sperm stained red. Percentage of morphologically abnormal spermatozoa, the slides stained with eosin-nigrosin, and the head, tail and total abnormality of spermatozoa was expressed (Zade et al., 2013; Manson et al., 1988).

Mating trial test

Each male rat was cohabitated overnight with proestrous females in a ratio of 1:2 and housed in a single cage. Positive mating was confirmed by presence of sperm and vaginal plug in the vaginal smear the following morning (Akaydin et al., 2014; Cankaya et al., 2014).

Body and sex organ weight

The initial and final body weights of the animals were recorded. The testes, epididymis, seminal vesicle and ventral prostate were dissected out, and weighed to the nearest milligram (Gopal

krishnan et al., 2014; Kulkarni et al., 2005).

Histopathological analysis

Testes and uteri were carefully dissected out following abdominal incision from male and female rats respectively and fixed in 10% normal-saline and processed routinely for paraffin embedding (Soni et al., 2013).

Reversible antifertility study

Hydroxytyrosol was given as (20mg/kg) (Maria et al., 2015), the normalization of fertility was performed using Hydroxytyrosol as an antioxidant agent, and male rats were given specified dose on basis of their body weight to evaluate the reversible of antifertility.

Statistical analysis

The consolidated mean data of bodyweight changes, food consumption, hematology and blood chemistry were analyzed by One-way ANOVA followed by Dunnet 't' test using -INSTAT-V3 computer software program.

Results

Particle size Analysis

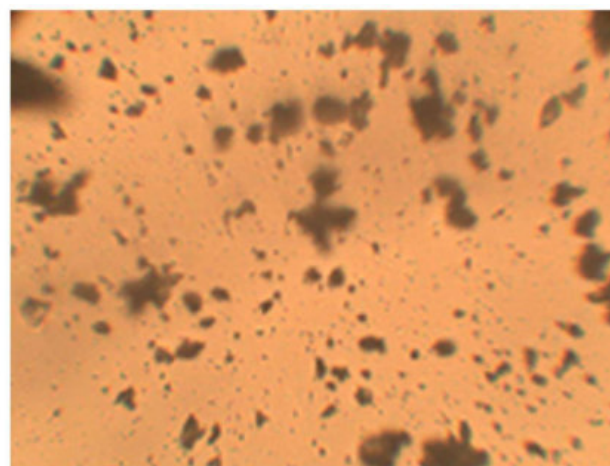


Figure 1. Particle size analysis of intended suspension

Table 1. Total count of particles with percentage

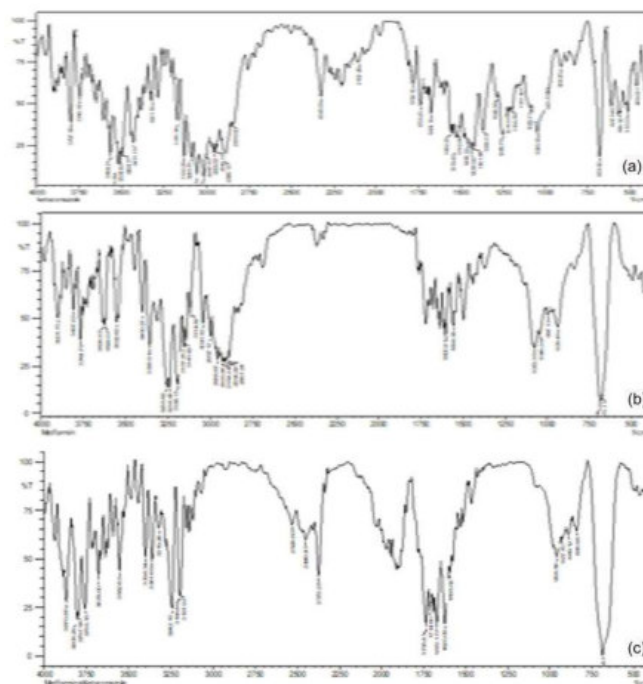
No. of particles	Count	% Count
# 10 to 5	298	78.0105
# 25 to 10	42	10.9948
# 310 to 20	29	7.5916
# 420 to 30	5	1.3089
# 530 above	8	2.0942

Table 1a. Total count of particles with statistical analysis

Parameters	Area in Square Microns	Aspect	Axis (Major)	Axis (Minor)	Area Eqv Dia Microns	Circularity (Eqv)
Min	.3515	0.8056	0.5844	0.5227	0.6594	0.5536
Max	986.9446	3.0781	62.033	37.8382	35.449	1.7725
Mean	26.1346	1.3584	4.2943	3.0086	3.5262	1.2176
Sum	9983.43	518.9058	1640.404	1149.268	1347.019	465.1346
Std. Dev	92.1349	.39	6.7573	4.5616	4.5655	.3232

Table 2. FTIR study for test drug

Sample	Functional Group	Wave Number (cm ⁻¹)
Ketoconazole	N=H Stretch	3800-3750
	N-H Stretch	3350-3310
	O-H Stretch	3420-3590
	C=O Stretch	1800-1700, 1830-1870
	C-N Stretch	1250-1050
	C=C Stretch	1710-1680
	C-C Stretch	1210-1163
	C-O Stretch	1250 -1020
Metformin	N-H Stretch	3350-3310
	C-H Stretch	2840-3000
Ketoconazole + Metformin	N-H Stretch	3350-3310
	O-H Stretch	3420-3590
	C=O Stretch	1800-1700, 1830-1870
	C-N Stretch	1250-1050
	C=C Stretch	1710-1680
	C-C Stretch	1210-1163
	C-O Stretch	1250-1020
	C-H Stretch	2840-3000
	N=H Stretch	3800-3700

**Figure 2.** FTIR Spectrum of (a) Ketoconazole (b) Metformin(c) ketoconazole+Metformin

Acute toxicity study

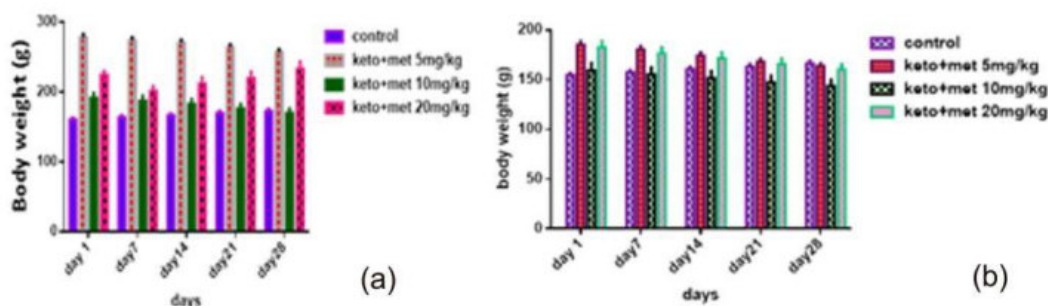
Rats received the fixed dose of Ketoconazole + Metformin (2000 mg/kg) showed some clinical signs of toxicity and death during the observational period of 14 days. There was some abnormal macroscopical changes observed like hepatomegaly and color changes in kidney of both male and female rats. No significant changes in the body weight gains were detected. All animals

survived at 50mg and no mortality was observed until the end of the experiment indicating that the median lethal dose (LD₅₀) of Ketoconazole + Metformin is higher than 100 mg/kg for Wistar albino rats.

Sub-acute toxicity study

Effect of Ketoconazole + Metformin on the general behaviour of rats

The oral administration of Ketoconazole + Metformin

**Figure 3.** Body weight (g) of animals exposed to Ketoconazole+ Metformin for 28 days: (a) Body weight (g) of male Wistar albino rats (b) Body weight (g) of female Wistar albino rats

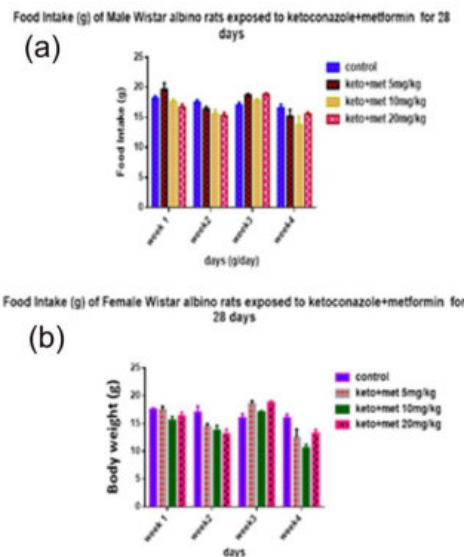


Figure 4. Food (ml/rat/day) intake of male and female Wistar albino rats exposed to Ketoconazole+ Metformin for 28 days: (a) Food intake of male Wistar albino rats (b) Food intake of female Wistar albino rats

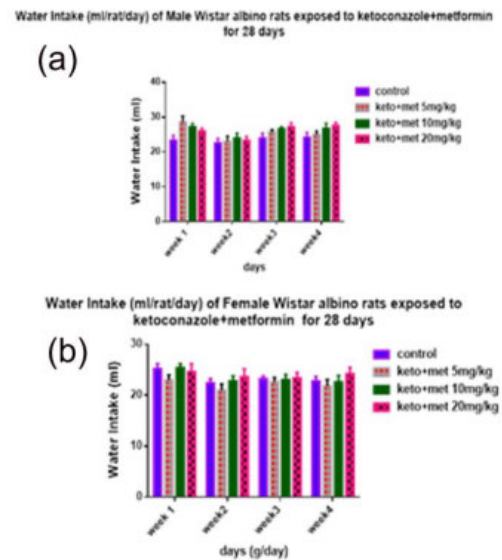


Figure 5. Water (ml/rat/day) intake of male and female Wistar albino rats exposed to Ketoconazole+ Metformin for 28 days: (a) Water intake of male Wistar albino rats (b) Water intake of female Wistar albino rats

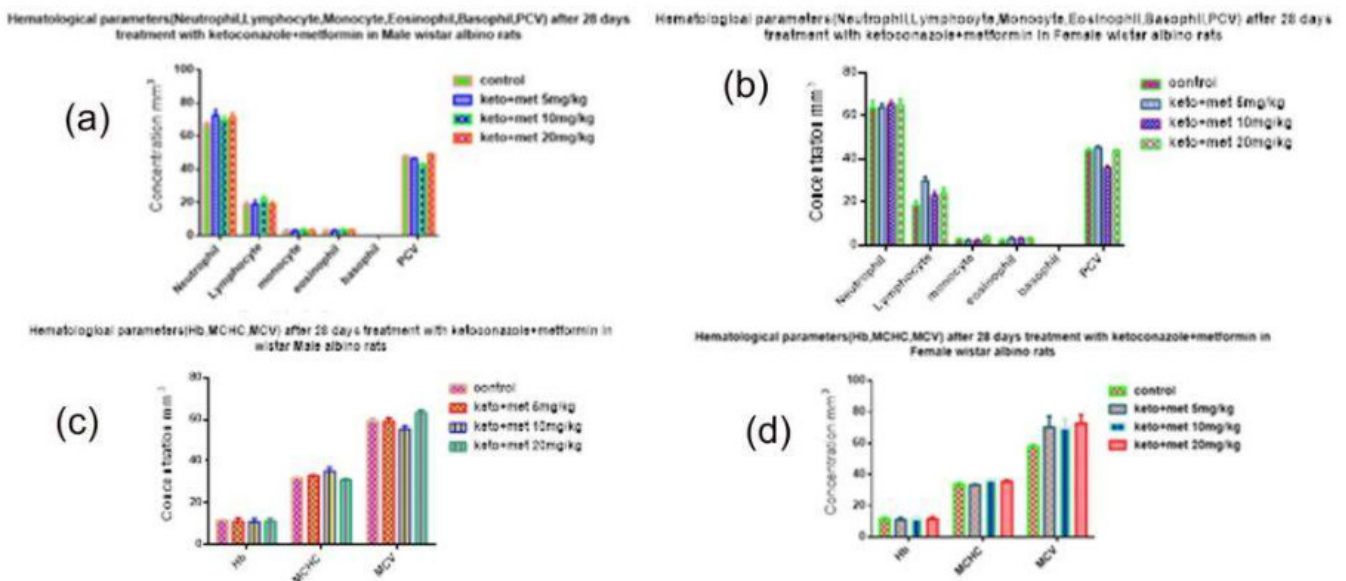


Figure 6. Hematological parameters (ml/rat/day) of male and female Wistar albino rats exposed to Ketoconazole+ Metformin for 28 days

caused no noticeable change in the general behaviour of the rats. There were no significant changes in body weight or food intake of the rats as compared to the animals of control group. In sub-acute treatment, 28-days administration of Ketoconazole + Metformin (5, 10 and 20 mg/kg) did not cause any mortality in rats. There was no sign of toxicity during the experimental period as compared to control.

Histopathological Investigation

In industrialized nations today, synthetic hormonal oral contraception is the most common practice for preventing

pregnancy. Both men and women are responsible for pregnancy, yet the burden of preventing it often falls on one gender. Since there are limited options for men there is strong urge for male contraceptive with safe effective and minimal side effect. Women can choose from a variety of options to control fertility while for generations, men have been limited to withdrawal, condoms and sterilization. But someday soon, a new method may allow men to shoulder a greater share of responsibility. Despite evidence suggesting that there are many possible dangers of birth control pills, millions of women choose to take these hormonal medications. Surely

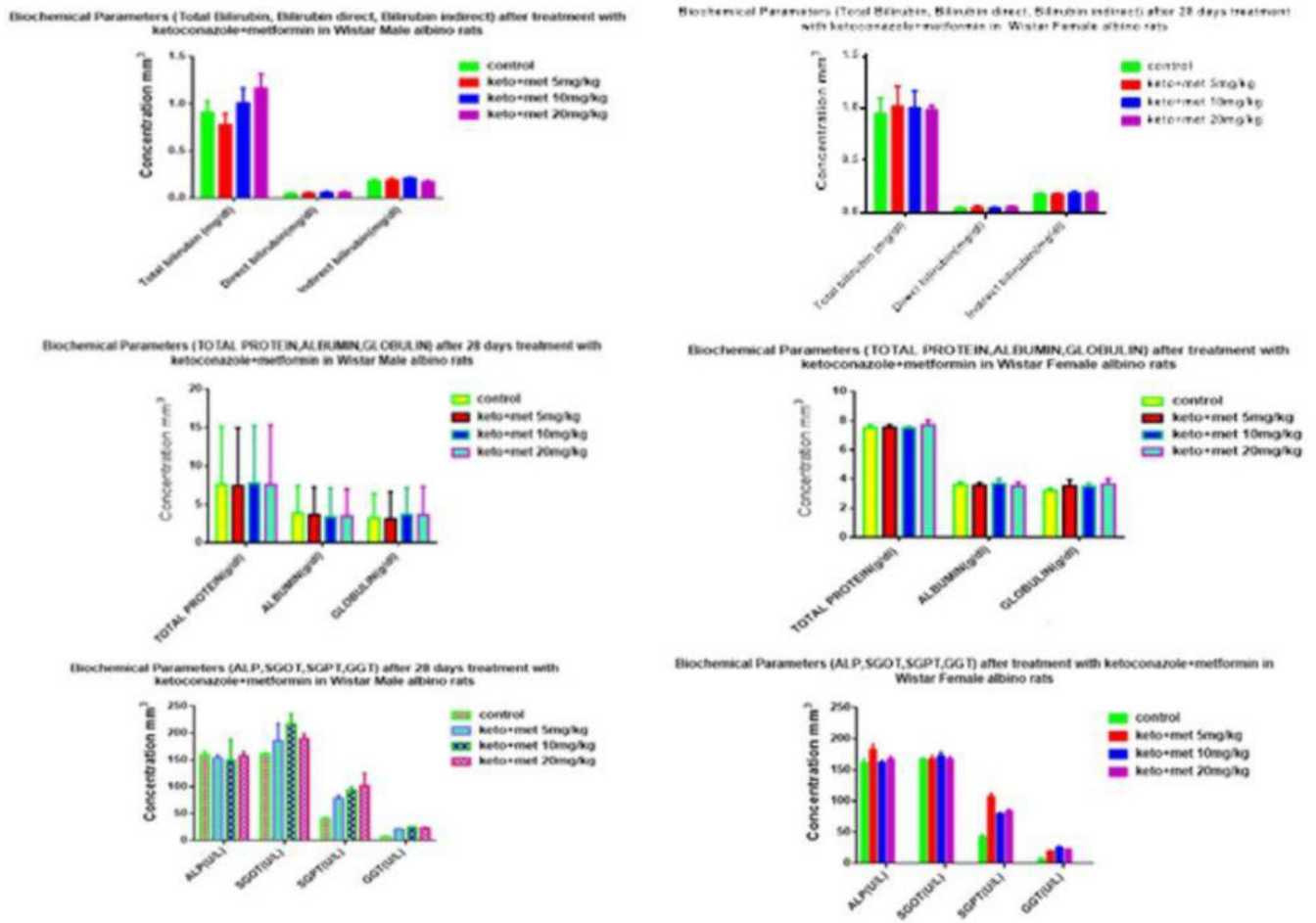


Figure 7. Effects on biochemical parameters (LFT) - after 28 days treatment with Ketoconazole+ Metformin in rats

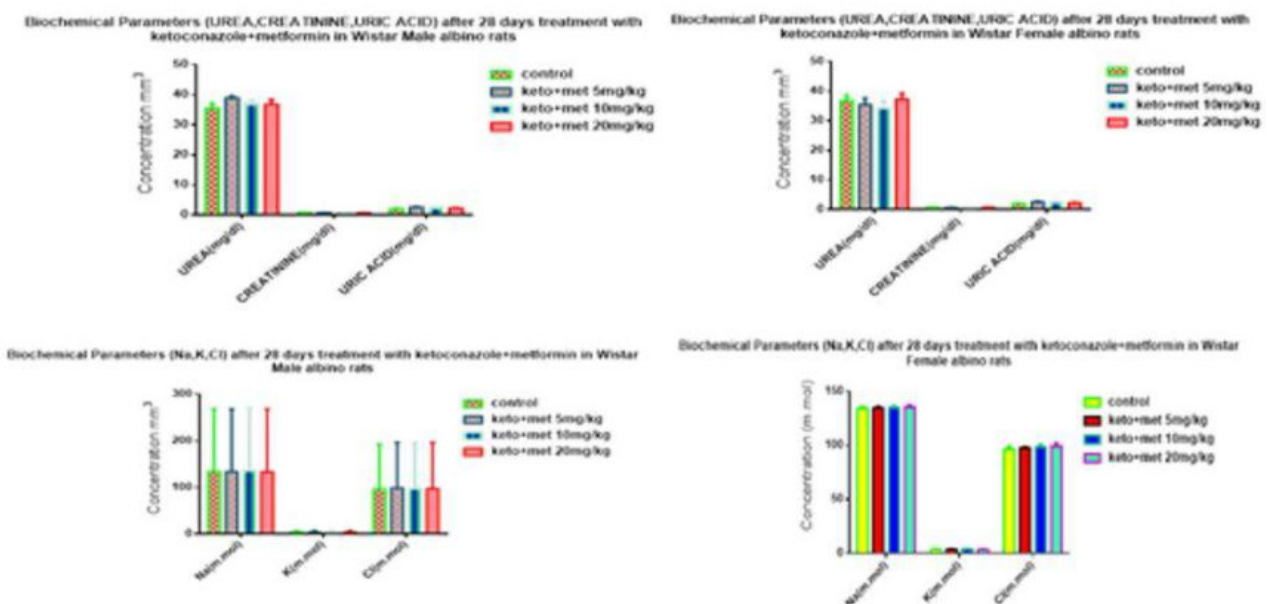


Figure 8. Biochemical parameters (RFT) - after 28 days treatment with Ketoconazole+ Metformin in rats




Figure 9. Effects on lipid profile- after 28 days treatment with Ketoconazole+ Metformin in rats




Figure 10. Histopathology of Bone of rat treated with metformin +ketoconazole: 9(a) Control- shows normal connective tissue with fibroblasts; 9(b) 5mg/kg - shows connective tissue with normal fibroblasts; 9(c) 10mg/kg - shows mild infiltrations with fibroblasts; 9(d) 20mg/kg - shows edematous connective tissue with fibroblasts.

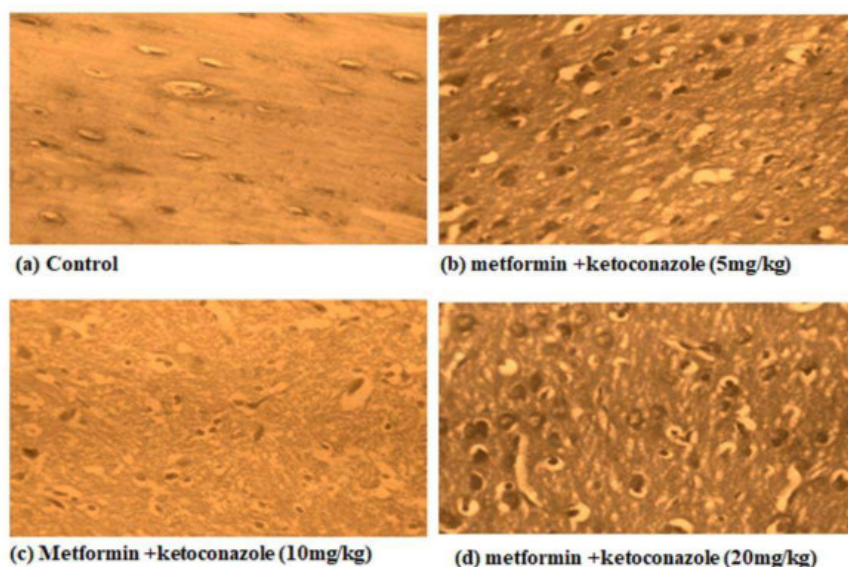


Figure 11. Histopathology of Brain of rat treated with Metformin +ketoconazole: 10(a) Control- shows normal nerve fibres and astrocytes; 10(b) 5mg/kg - with normal astrocytes and nerve fibres; 10(c) 10mg/kg- shows normal nerve fibres and astrocytes; 10(d) 20mg/kg- shows normal nerve fibres and astrocytes.

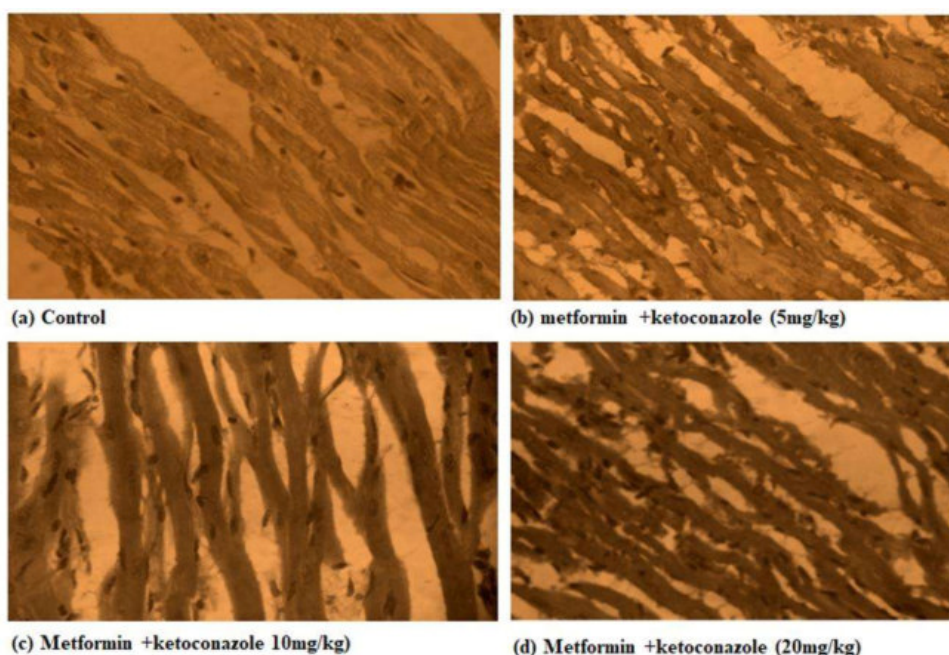


Figure 12. Histopathology of Heart of rat treated with metformin + ketoconazole: 11(a) Control- normal myocytes and cardiac muscle bundles; 11(b) 5mg/kg- with normal myocytes and muscle fibres; 11(c) 10mg/kg- cardiac muscle fibres and myocytes appear normal and no haemorrhage seen in the muscle bundles; 11(d) 20mg/kg myocytes and cardiac muscle bundles appear normal.

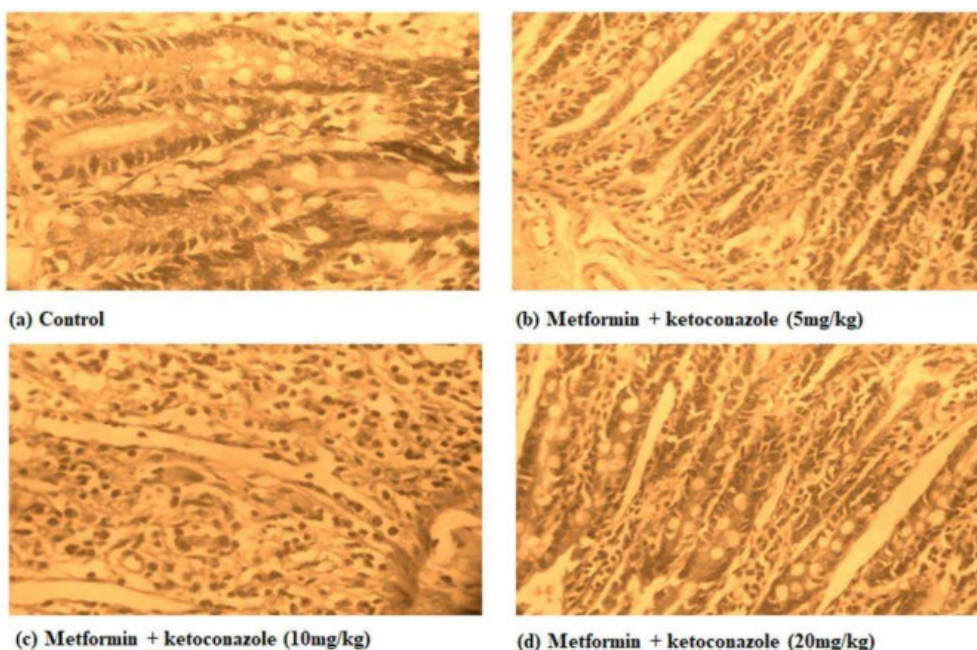


Figure 13. Histopathology of Intestine of rat treated with metformin + ketoconazole: 12(a) Control- shows prominent columnar epithelial cells and mucus secretion; 12(b) 5 mg/kg - with prominent columnar epithelial cells, mucus secretion and mild infiltrations; 12(c) 10mg/kg - shows prominent mucus secretion; 12(d) 20mg/kg- shows prominent columnar epithelial cells and mucus secretion.

the side effects make birth control pills a less than desirable option for contraception in females. And now heart disease has

become the leading cause of death among women, due to widespread and long-term use of oral contraceptives.

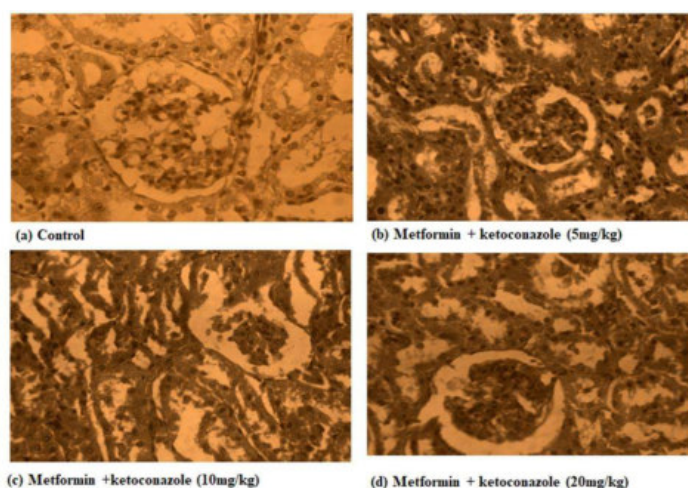


Figure 14. Histopathology of Kidney of rat treated with Metformin +ketoconazole: Fig 13 Control- shows normal renal tissue with glomeruli and tubule; Fig 13(b) 5 mg/kg- shows normal glomeruli and renal tubules and mild infiltration of cells Fig 13(c) 10 mg/kg- shows renal tissue with tubular damage and Glomeruli show mild shrinkage; Fig 13(d) 20 mg/kg - shows renal tissue with tubular epithelial damage and normal glomeruli.

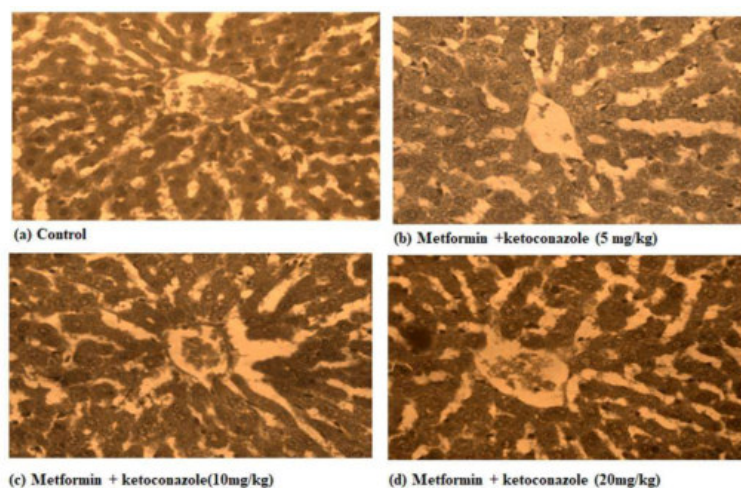


Figure 15. Histopathology of Liver of rat treated with metformin +ketoconazole: 14(a) Control- shows normal hepatocytes and infiltration of mononuclear cells; 14(b) 5 mg/kg - with mild congestion and infiltration of mononuclear cells; 14(c) 10 mg/kg - mild edema, congestion of blood vessels; 14(d) 20 mg/kg - dilatation of sinusoids and infiltration of mononuclear cells.

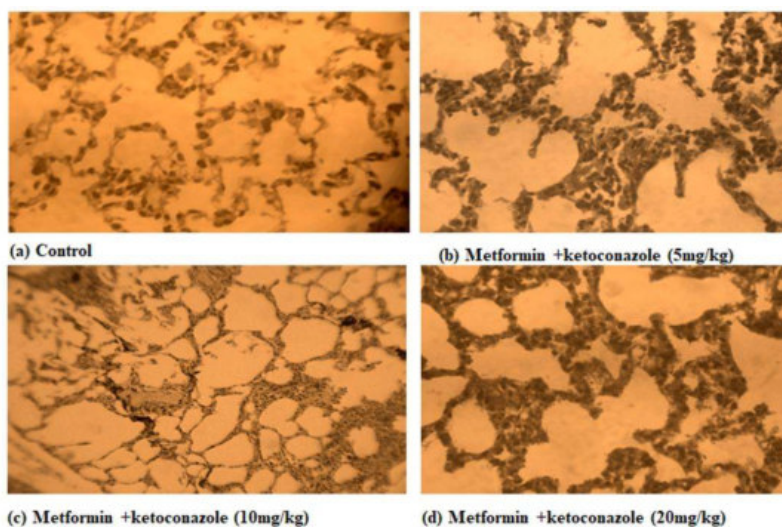


Figure 16. Histopathology of Lungs of rat treated with metformin +ketoconazole: 15(a) Control- shows normal alveoli; 15(b) 5mg/kg- mild congestion of alveolar tissue 15(c) 10 mg/kg- Congested alveolar wall is seen; 15(d) 20 mg/kg- mild congestion of alveolar tissue with mild alveolar septal edema.

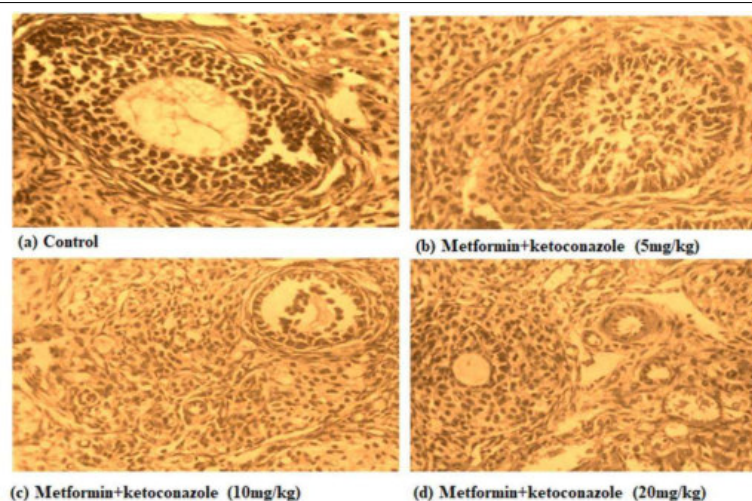


Figure 17. Histopathology of Ovary of rat treated with metformin+ketoconazole: 16(a) Control- shows ovarian stroma with follicles and Corpus luteum; 16(b) 5mg/kg - shows normal ovarian follicles and Corpus luteum; 16(c) 10mg/kg- shows normal ovarian follicles and Corpus luteum; 16(d) 20mg/kg- shows normal ovarian follicles and Corpus luteum.

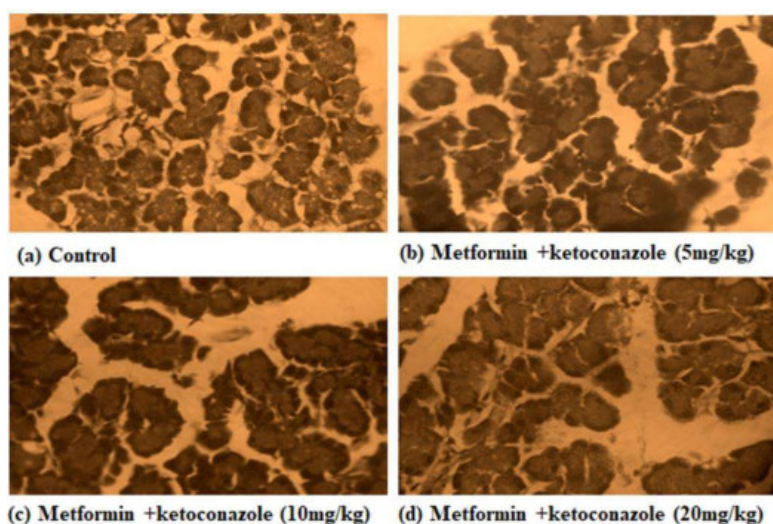


Figure 18. Histopathology of Pancreas of rat treated with metformin +ketoconazole: 17(a) Control- shows pancreas with normal acini and islet cells; 17(b) 5mg/kg - shows pancreas with normal acini and islet cells; 17(c) 10 mg/kg - shows pancreas with normal acini and islet cells; 17(d) 20 mg/kg - shows pancreas with normal acini and islet cells.

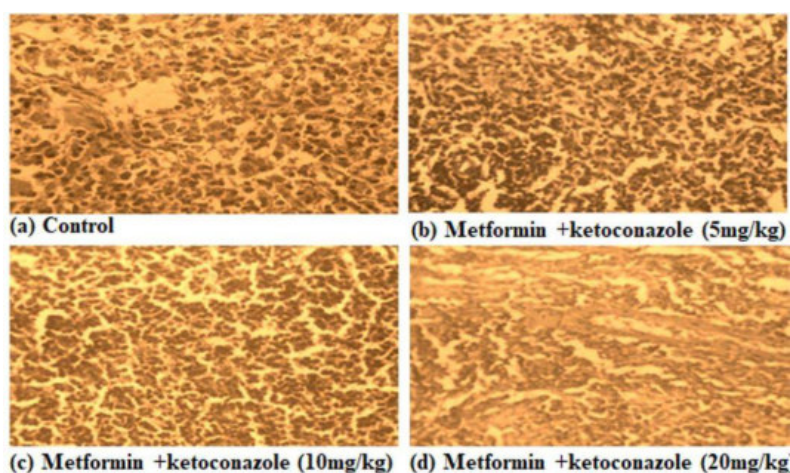


Figure 19. Histopathology of Spleen of rat treated with metformin +ketoconazole: 18(a) Control- shows normal spleen with lymphoid aggregation; 18(b) 5mg/kg - shows lymphoid hyperplasia; 18(c) 10 mg/kg - shows lymphoid hyperplasia; 18(d) 20 mg/kg- shows congestion with lymphoid hyperplasia.

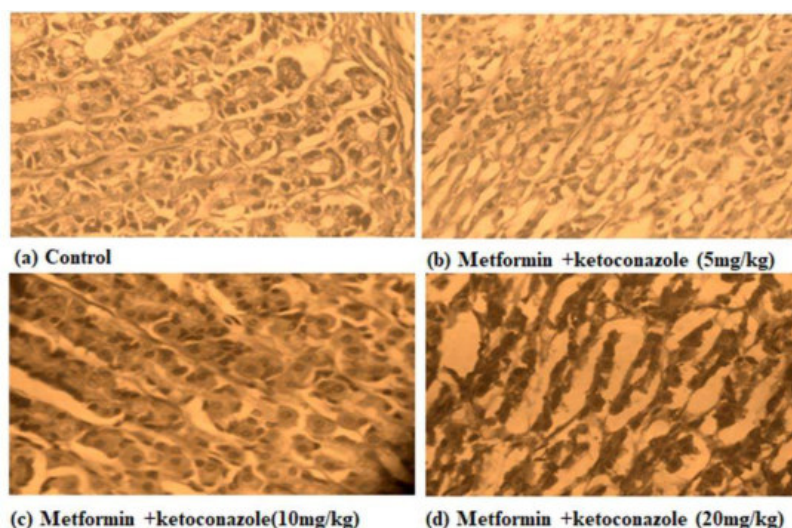


Figure 20. Histopathology of Stomach of rat treated with metformin + ketoconazole: 19(a) Control- shows normal mucosal glands with columnar epithelial cells; 19(b) 5 mg/kg- shows near normal mucosal gland; 19(c) 10 mg/kg - shows normal mucosal glands with columnar epithelial cells; 19(d) 20 mg/kg - shows hyperplastic mucosal glands, congestion and superficial erosion.

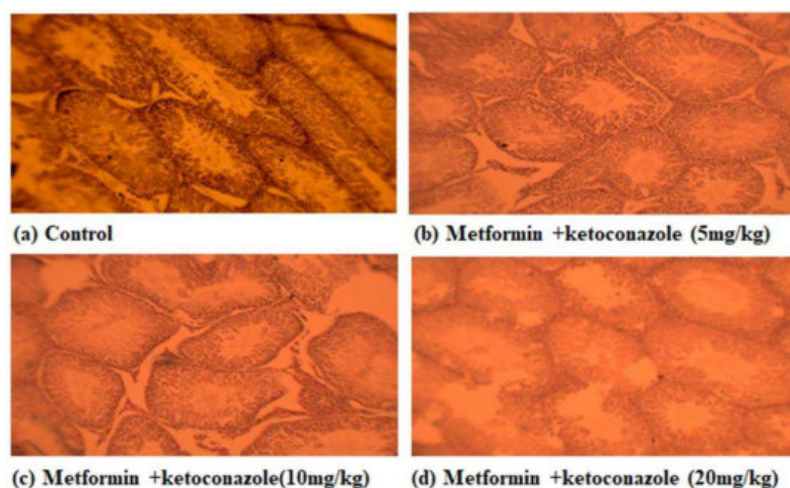


Figure 21. Histopathology of Testes of rat treated with metformin + ketoconazole: 20(a) Control- shows normal seminiferous tubules with spermatogenesis; 20(b) 5mg/kg - seminiferous tubules with mild abnormal spermatogenesis; 20(c) 10mg/kg - seminiferous tubules with abnormal spermatogenesis; 20(d) 20mg/kg - seminiferous tubules with complete abnormal spermatogenesis.

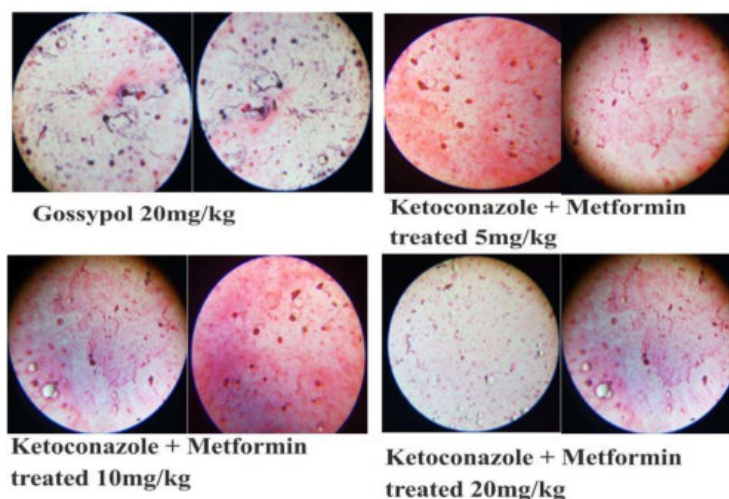


Figure 22. Sperm counts (millions/mL) and sperm morphology

Table 3. Sperm counts (millions/mL) and sperm morphology

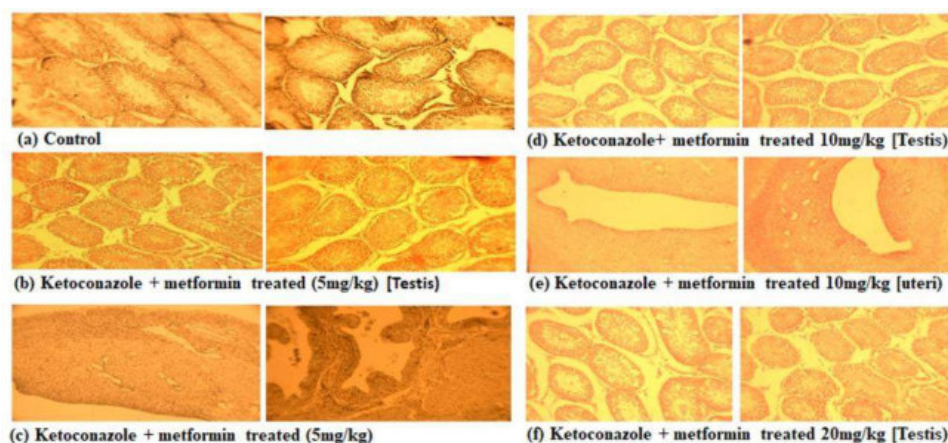
Groups	Sperm count	Tail less	Headless	Body twisted	Tail round	Head round	Total
I	50.145 ± 0.304	3%	1%	-	-	-	4%
II	13.63 ± 0.109*	3.5%	2.5%	1.5%	2%	1%	10.5%

Values are expressed as mean ± SEM. * $P < 0.05$ between control and treated groups. N=6.

Table 4. Aspects of sperm parameters of ketoconazole + Metformin treated rats

Group	Ketoconazole +Metformin			
	Control	DAY 30	DAY 60	DAY 90
Weight change (%)	153 ± 3	151 ± 6.2**	181 ± 8.3**	183 ± 5.3**
Sperm Count. (mL/cauda) X10 ⁶	69 ± 4	50 ± 6.3*	71 ± 7***	76 ± 4.8***
Motile sperm (%)	64 ± 2	51 ± 2.4**	74 ± 5.9***	77 ± 2.9***

Values are expressed as mean ± SEM. * $P < 0.05$ between control and treated groups. N=6.

**Figure 23.** Effect of Ketoconazole + Metformin on testis of rats

Recently it has been found that metformin decreases testosterone production *in vitro* and reduces testicular size and the population of Sertoli cells *in vivo* (Tartarin et al., 2012), this reduction in Sertoli cells population was due to a decrease in cell proliferation rather than cell death (Tartarin et al., 2012), indicating that metformin alters the physiological functions of Sertoli cells (Weber et al., 1983) (Rato et al., 2010), and also for providing the nutritional and physical support for the developing germ cells (Rato et al., 2012b).

Ketoconazole was shown to lower circulating testosterone levels in men following the oral doses of 200-600 mg/day standard for antifungal therapy (Pont et al., 1982a). Additional studies *in vitro* demonstrated a direct effect of ketoconazole on rat testicular cells (Feldman, 1986). Experiments in men by (Santen et al., 1983), revealed an effect of ketoconazole on C17₂₀ lyase, the enzyme in testicular steroidogenesis that catalyzes the synthesis of androstenedione from 17 α -OH progesterone. Work *in vitro* using rat testes demonstrated an additional blockade of

steroidogenesis at 17 α -hydroxylase (Sikka et al., 1985). Following the finding of an inhibition of adrenal steroidogenesis by Ketoconazole (Pont et al., 1982b, Loose et al., 1983) reported the mechanism of this inhibition and demonstrated blockade by Ketoconazole of two adrenal P450 steroidogenic enzymes, at 11-hydroxylase (catalyzing deoxycorticosterone to corticosterone) and at the side chain cleavage enzyme (catalyzing cholesterol to pregnenolone). Research on the ovarian effects of KCZ originally focused on aromatase and 17 β -estradiol synthesis (Watanabe and Menzies., 1985, 1986a; Malozowski et al., 1986; Latrille et al., 1987). *In vivo* and *in vitro* effects of ketoconazole on sperm motility, suggests that the reduction in sperm motility is not related to a decrease in steroid levels. (Heckman et al., 1992). From this literature background we can assume that Ketoconazole in combination with metformin probably would be a viable approach for the development of a reversible male contraceptive as an ideal antifertility agent.

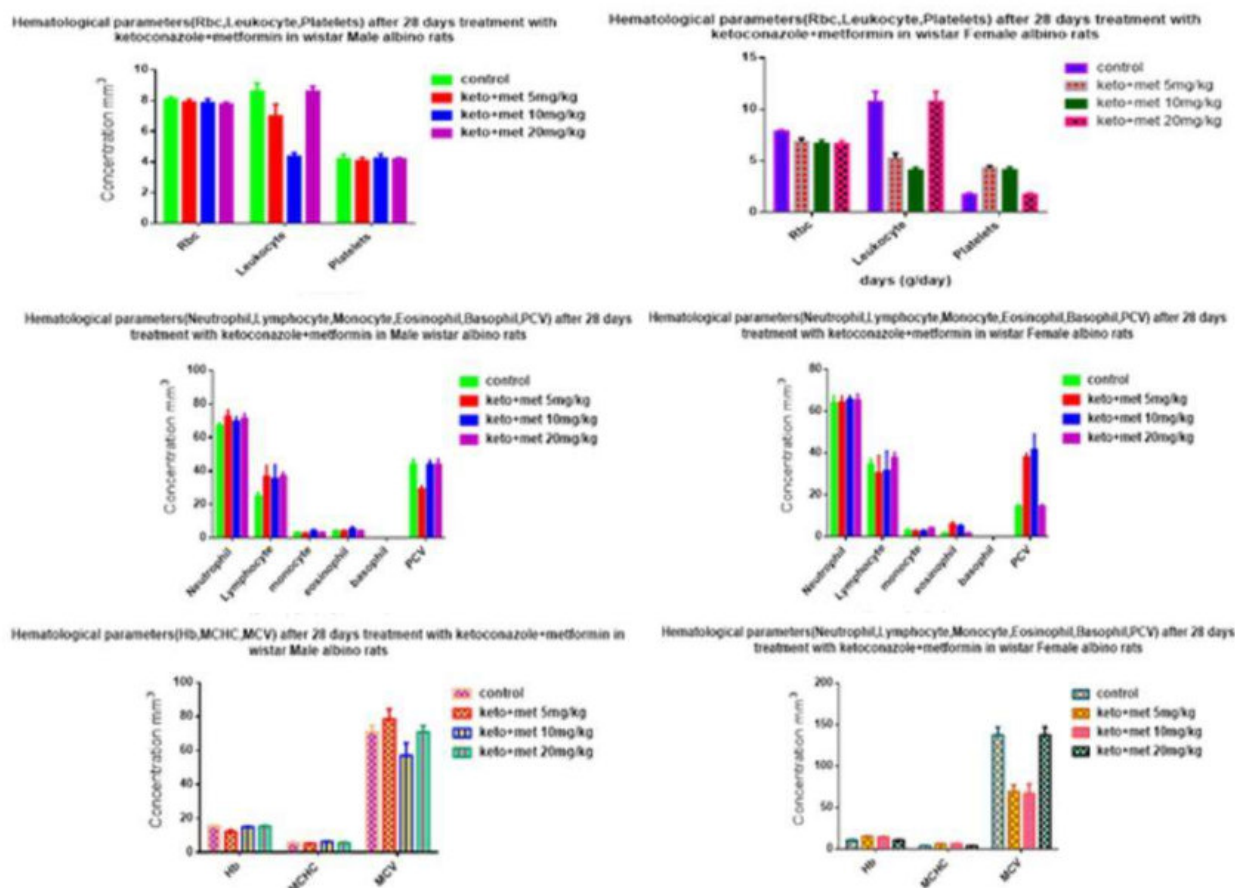


Figure 24. Estimation of hematological parameters on rats

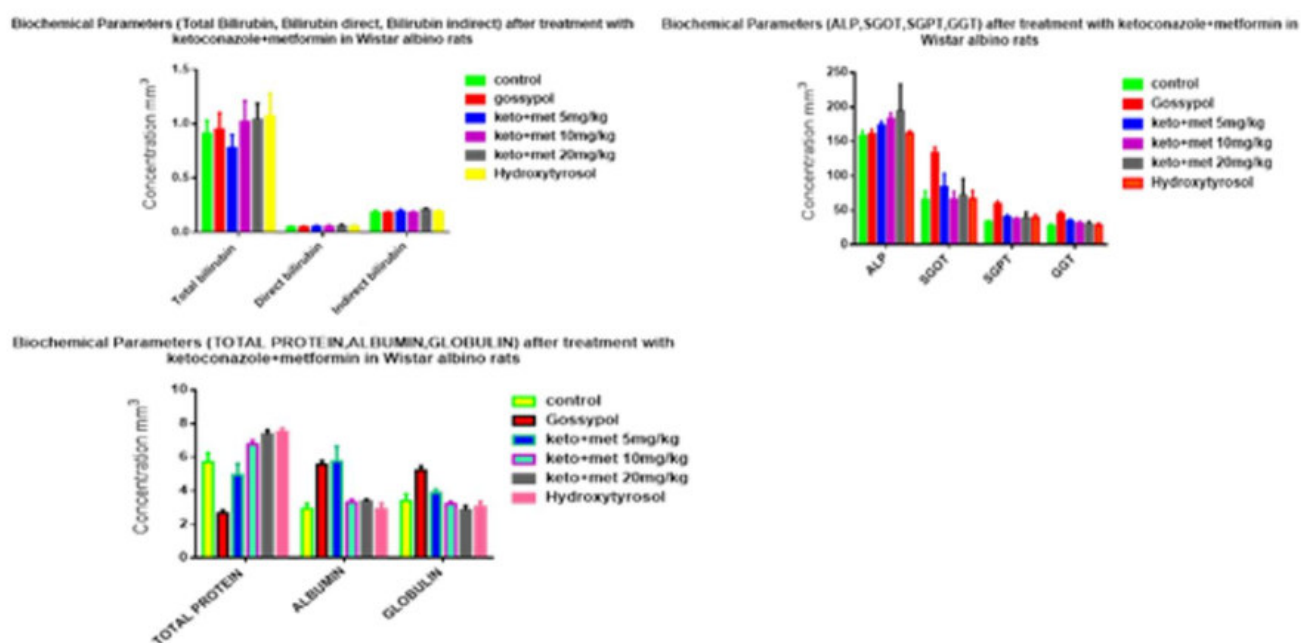


Figure 25. Effect of Ketoconazole + Metformin on biochemical parameters

In the present study, the acute toxicity study following OECD guidelines 423 (Walum et al., 1988), showed that Ketoconazole + Metformin up to 100 mg/kg are non-toxic and safe whereas in the sub-acute toxicity there were no significant adverse effects on the

hematological parameters and in biochemical parameters only SGPT, SGOT and creatinine levels increases in high doses of Ketoconazole + Metformin. So, it may be confirmed that the Ketoconazole + Metformin did not induce any noteworthy




Figure 26. Lipid profile after treatment with Ketoconazole+ Metformin in rats

damage to the vital organs (Sharma et al., 2015).

According to the OECD guidelines 407 (Yamasaki et al., 2002) rodents were most widely used animals for general toxicologic, carcinogenic, pharmacokinetic and toxicokinetic studies. Antifertility studies are useful to identify the level of damage induced by synthetic medicine. Antifertility study may cause damage to spermatogenesis. Rats were administered with Ketoconazole + Metformin daily by oral gavage at doses of 25, 50 and 100 mg/kg for 28 days. The Ketoconazole + Metformin treated male rats showed very high mortality, where rats were unable to sustain at this dose level and then dose were revised to 5, 10 and 20 mg/kg with no mortality.

The animals after dosing for 14 days were dissected (Soni et al., 2013), and there was mild reduction of epididymis and accessory sex organ weights, spermatid retention in the seminiferous tubules, decrease of testosterone and increases of estradiol, luteinizing hormone (LH) and Follicular Stimulating Hormone (FSH). A prolongation of the estrous cycle and increases of estradiol, LH and FSH were observed in the treated female rats. (Shin et al., 2006). The normalization of fertility was accomplished using Hydroxytyrosol as an antioxidant reagent, to reverse the effect of Ketoconazole + Metformin and bring back testicular hormones to normal.

Conclusion

The safer with least side effects approach to male contraception continues as a new research beam. A number of sperm inhibiting targets for non-hormonal male contraception have been a great challenge. Presently, one of the biggest hurdles in the male contraceptive development lies in identifying pharmacological agents that reliably render males infertile and are fully reversible and safe for long-term use, as men might use these medications for many years. In the present investigation, an attempt has been made to formulate and evaluate Ketoconazole as a male antifertility drug and assess the influence of Metformin with Hydroxytyrosol in normalization of infertility in rats. To fix the combinational therapeutic dose the toxicological assessment was done and found to be non-toxic at maximum of 20mg/kg

dose level.

Based on the results obtained in this study, it can be concluded that this combination of drugs can be used to induct safe and reversible male infertility. Further investigation is required to assess and prove the upper dose limit for complete cessation of fertility by Ketoconazole and the exact dose required to reverse the antifertility response preclinical and also clinically.

Acknowledgement

Authors are grateful to Dr. V. Madhavan, Dean, Faculty of Pharmacy, M.S.R.U.A.S., Bangalore, for providing all the facilities to carry out this research.

Conflict of Interest

The authors declare no conflicts of interest

References

- Agarwal A, Allan JJ. 2010. Antifertility effects of herbs: need for responsible reporting. *Journal of Ayurveda Integrated Medicines*, 2:129-131.
- Akaydin G, Tatli-Çankaya I, Alqasoumi SI, Abdel-Rahman RF, Yusufoglu H, Anul SA. 2014. Evaluating the antifertility potential of the ethanolic extracts of *Bupleurum sulphureum* and *Cichorium intybus* in male rats. *Asian Journal of Pharmaceutical Clinical Research*, 7:211-218.
- Anderson RA, Baird DT. 2002. Male Contraception, *The Endocrine Society*, 6:735-762.
- Anderson RA, Baird DT. 2002. Male contraception. *Endocrine Review*, 23(6): 735-62.
- Gray AL, Smit JA, Manzini N, Beksinska M. 2006. Systematic review of contraceptive medicines "Does choice make a difference?" Systematic review: contraceptive choice, 1:1-58.
- Kamischke A, Venherm S. 2000. Intramuscular Testosterone Undecanoate and Norethisterone Enanthate in a Clinical Trial for Male Contraception. *The Journal of Clinical*

- Endocrinology & Metabolism, 1:86.
- Bhatia DK, Sharma AK, Pathania PC, Khanduri NC. 2010. Antifertility effects of crude different of *Adiantum tumululatum* Burm. On reproductive organs of male albino rats. Biological Forum, 2:88-93.
- Bhaves D, Chetan G, Bhat KM, Shivprakash. 2007. Estimation and pharmacokinetics of metformin in human volunteers. Indian Journal of Pharmaceutical Education and Research, 2:135-139.
- Clark H, Rao SR, Machiyama K. 2017. London School of Hygiene and Tropical Medicine; Nandita Thatte. World Health Organization 1:72-92.
- ES Watkins. 2012. How the Pill Became a Lifestyle Drug: The Pharmaceutical Industry and Birth Control in the United States Since 1960. American Journal of Public Health, 8:1462-1472.
- Gopal krishnan B, Shimpi SN. 2011. Antifertility effect of *Madhucalatifolia (roxb) Macbride* seed extract. International Journal of Applied Biology and Pharmaceutical Technology 4:49-53.
- Govindaraj Y, Melanaphuru V, Gupta S, Agrahari V, Nema RK, Govindaraj Y. 2009. Antifertility activity of the ethanolic extract of *Cassia occidentalis*, *Derris brevipes* variety *Brevipes* and *Justicia simplex*. World Journal of Chemistry, 2:118-122.
- Kulkarni TR, Kothekar MA, Mateenuddin M. 2005. Study of anti-fertility effect of lemon seeds (*Citrus limonum*) in female albino mice. Indian Journal of Physiology and Pharmacology, 3:305-312.
- Manson JM, Zenick H, Costlow D. 1988. Teratology test methods for laboratory animals. In: Wallace-Hayes A, editor. Principle and Methods of Toxicology. New York: Raven Press, 6:141-184.
- Martin CW. Anderson, RA. 2000. Potential impact on hormonal male contraception: cross cultural implications for development of novel preparations, Human Reproduction, 15:637-645.
- Ramya R, Sivasakthi R, Senthilkumar C, Anudeepa J, Santhi N, Venkata Narayanan R. 2011. Preliminary phytochemical and antifertility studies on *Dodonea viscosa* Linn. Asian Journal of Pharmaceutical Research and Health Care, 3:77-79.
- Reddy SD. 2008. Recent Advances in Hormonal Contraceptives for Women. International Journal of Pharmaceutical Sciences and Nanotechnology, 3:199-206.
- Alexander J, Andersson HC; Bernhoft A, Brimer L, Cottrill B, Fink-Gremmels J, Jaroszewski J and Sørensen H. 2008. Gossypol as undesirable substance in animal feed. EFSA Journal, 908:1-55.
- Sharma P, Manjusha Rani S, Malhotra H, Nitesh, Deswal S. 2015. Antifertility potential of hydroalcoholic extract of *Cordiadichotoma G Forst*. Leaves: a Folk medicine used by Meena community in Rajasthan state in India. Asian Pacific Journal of Reproduction, 2:100- 105.
- Shinde N, Chauhan AS, Gupta SK, Bodakhe SH, Pandey DP. 2015. Antifertility studies of *Curcumin* and *andrographolide* combination in female rats. Asian Pacific Journal of Reproduction, 3:185-191.
- Singh R, Ali A, Jeyabalan G, Semwal A, Jaikishan. 2013. An overview of the current methodologies used for evaluation of aphrodisiac agents. Journal of Acute Disorder, 2:85-91.
- Soni P, Siddiqui AA, Dwivedi J, Soni V. 2013. Antioviulatory and estrogenic activity of leaves of *Datura stramonium* Linn. in female albino rats. Asian Journal of Pharmaceutical Research and Health Care, 2:65-71.
- United Nations, Department of Economic and Social Affairs, Population Division. 2015. Trends in Contraceptive Use Worldwide, 4:3-58.
- Welling LLM. 2016. Synthetic hormone dose in hormonal contraceptives predicts individual differences in personality. Society of Behavioral Research Practice, 1:13-16.
- Zade V, Wikhe M, Dabhadkar D, Dawada S, Patil U. 2013. Antifertility efficacy of *Cannabis sativa* leaves on female albino rats. International Journal of Scientific Progress & Research, 2:107-117.